



# Summary Feedback

(Combined feedback broadcasted at multiple times this week)

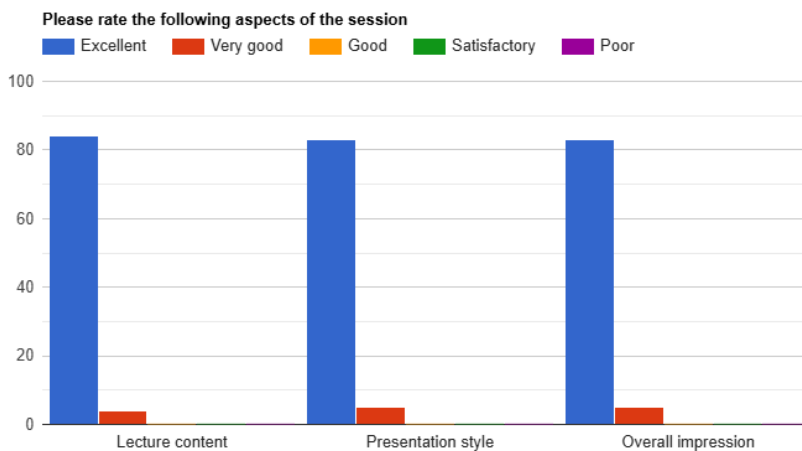
## PRE-RECORDED: Basildon FRCR 2B 'A to Zee' Course 2020

### Session 34/40

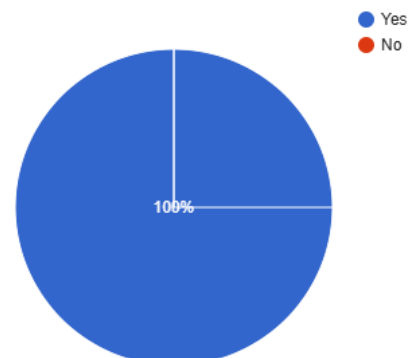
**Urology for FRCR  
(18<sup>th</sup> & 19<sup>th</sup> January 2025)  
Lecturer: Imran Syed**

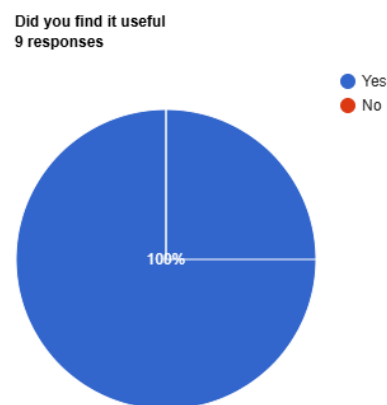
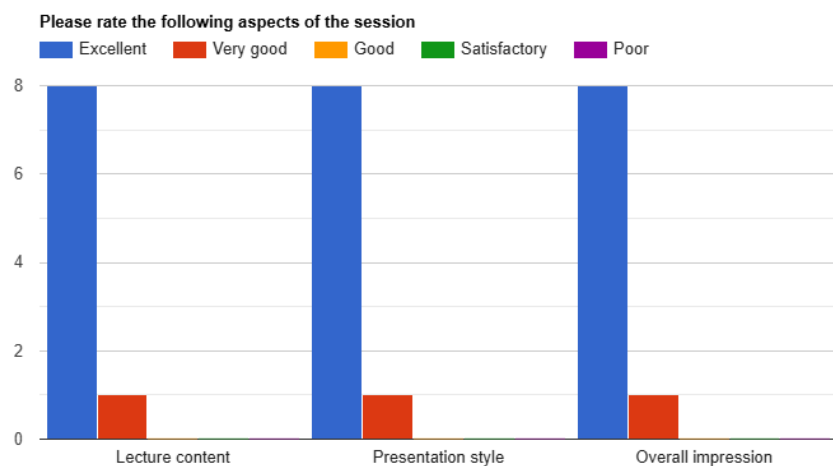
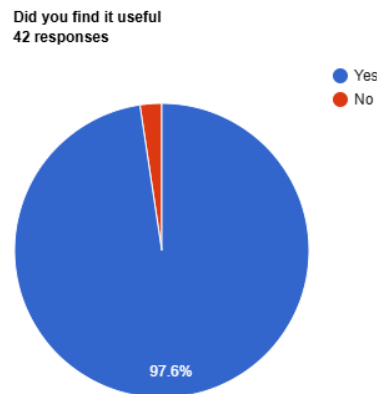
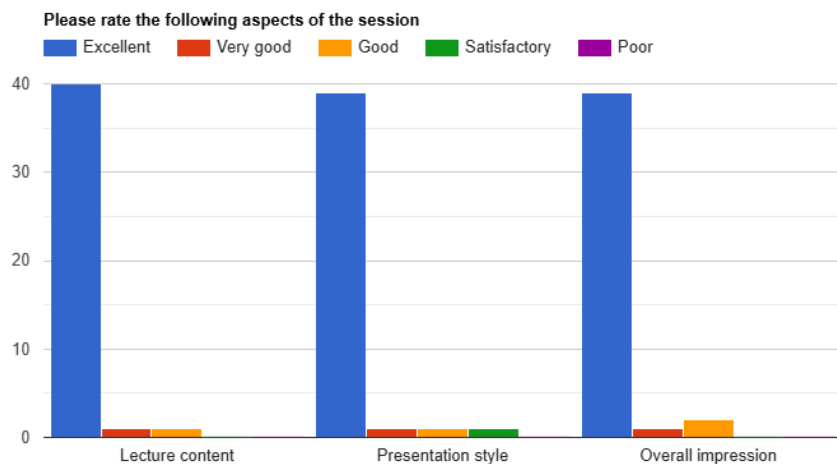
#### Summary Points:

- Total Attendees: 416 from 32 Countries (Algeria, Australia, Bangladesh, Dominica, Egypt, Ghana, Hong Kong, India, Indonesia, Iraq, Ireland, Jordan, Kenya, Libya, Malaysia, Myanmar, Netherlands, Nigeria, Oman, Pakistan, Poland, Saudi Arabia, South Africa, Sri Lanka, Sudan, Swaziland, Türkiye, UAE, UK, Yemen, Zambia, Zimbabwe).
- Total duration: 3 hours (each session broadcasted thrice during the week)
- Total feedback received from 139 participants, from three different broadcasts



Did you find it useful  
88 responses



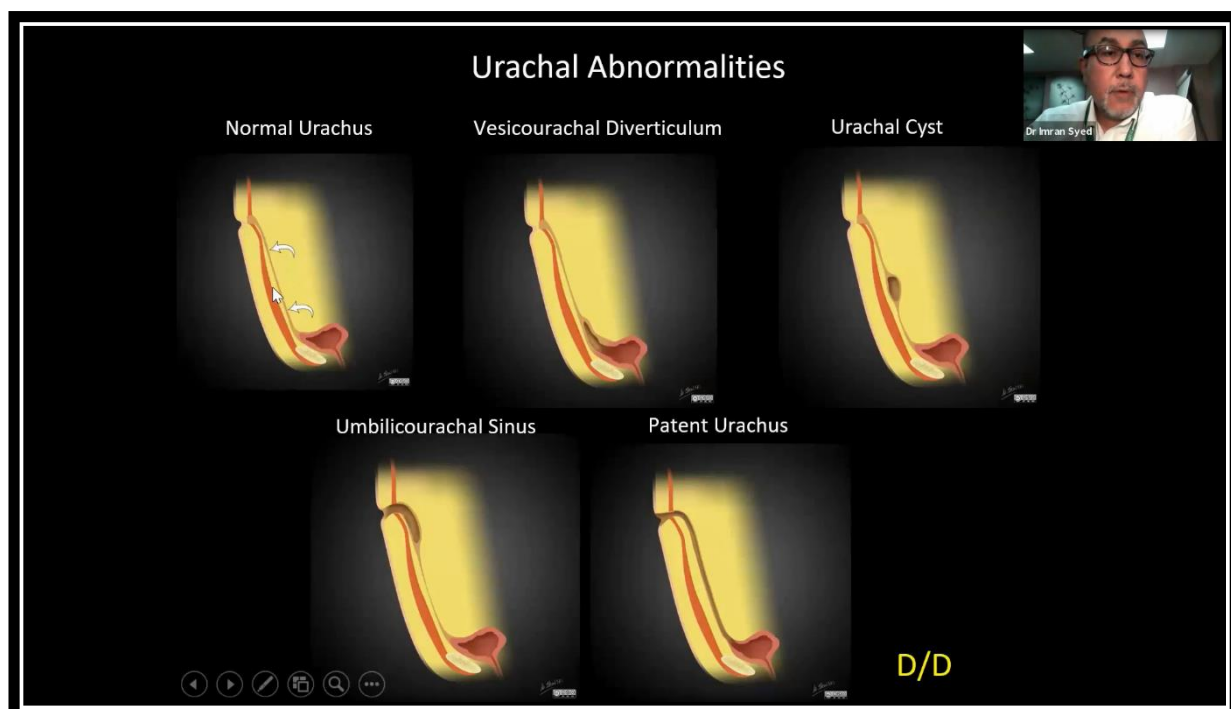
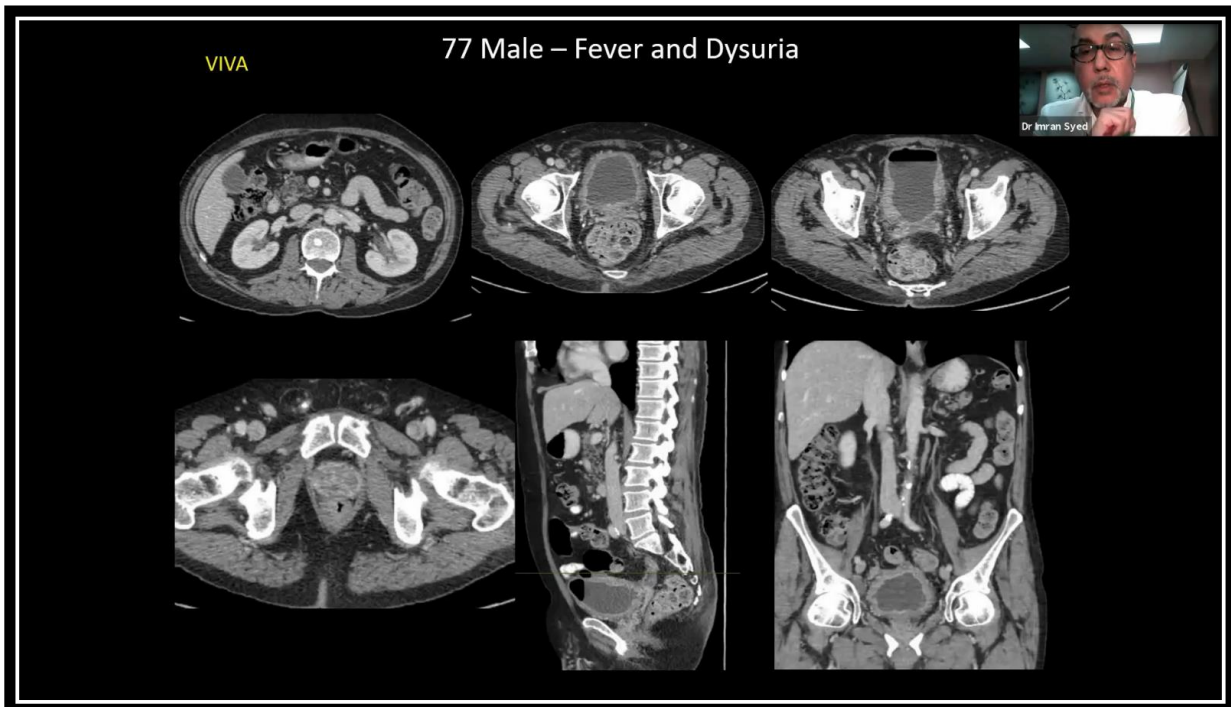


## Testimonials

- I found this lecture extremely useful. The content was clearly presented and covered all aspects of the topic comprehensively. Thank you for delivering such an informative session (UK).
- The lecturer was very well organized, showed many cases, and was always to the point. Supported the cases with explanatory slides! (Netherlands).
- The individual case based approach, detailed explanation of the basics like reading MRI prostate gland with emphasis on the exam oriented questions were excellent (India).
- Excellent session by Dr. Imran Syed, exam cases beautifully explained! (Pakistan).
- Thank you for the great knowledge (Sudan).
- Excellent classes and good cases. Great effort of teachers to teach us so selflessly (UAE).
- Thanks is not enough. We are very grateful sir (Egypt).
- Superb teaching (Malaysia).
- Dr. Imran Syed is a genius (Pakistan).
- Very, very good. God protect you! (Iraq).
- Very helpful. Brilliant lecture (India).
- Excellent teaching session (Algeria).
- Well-structured teaching pattern, clear guidance for exam oriented cases with detailed & easy explanation (India).


- Very good explanation & excellent cases based on images (Türkiye).
- Really awesome session. Much useful. Thank you so much (UAE).
- Impressive lecture content (Zimbabwe).
- Cases selection and description of prostatic tumors were the best aspects (UAE).
- Very nice session (Sudan).
- Nice cases, well explained by Dr. Imran (Pakistan).
- Very good cases (India).
- Details, GU organs, evaluation and assessment was presented in a systematic review (UAE).
- Viva case and follow up lecture were great (Malaysia).
- All aspects of the topic were very useful (UK).
- Very constructive teaching sessions with lots of cases (UK).
- Very good revision session. Thank you DKT team. Exceptional as always! (Pakistan).
- Broad coverage and the depth of teaching and prostate MRI was amazing (Zimbabwe).
- Excellent lecture and cases (Pakistan).
- Excellent informative lecture (UK).
- Excellent lecture (India).
- Informative (Saudi Arabia).
- Good intense teaching (UK).
- Excellent teaching session (Nigeria).
- Brilliant (UK).
- Incredibly useful lecture (UK).
- Extremely helpful (Pakistan).
- Excellent summary (UK).
- Good teaching (India).
- Wonderful session (Pakistan).
- It's perfect, thanks a lot (Egypt).
- Good explanations and selection of cases (UK).
- 100000/10 (Pakistan).
- Interaction of colleagues made me learning from their mistakes (UK).
- Excellent lecture with good exam oriented cases (India).
- Perfect (UK).
- Very detailed explanation on prostate CA (Malaysia).
- Description of basic anatomy on imaging and relevant pathology was excellent (Pakistan).
- All aspects were valuable (Pakistan).
- Excellent lecture (India).
- Valuable information shared in this session (Algeria).
- Good explanation (Pakistan).
- All the cases were discussed in detail (Pakistan).
- All aspects were helpful (Sudan).
- It was perfect (UAE).
- Descriptiveness and discussion were amazing (Pakistan).
- All of it was very useful & highly valuable (Egypt).
- Cases and teaching were amazing (Saudi Arabia).
- Great coverage of prostate cancer and PAN (UK).
- Cases were interesting and exhaustive (India).
- The teaching sessions were excellent (Nigeria).
- Great session (Libya).
- The range of the cases covered was amazing (UK).
- Very thorough. Good range of cases (UK).

- Amazing session (Iraq).
- Great cases (Iraq).
- Good illustration and explanation of unseen and rare cases (Pakistan).
- I loved the gentle teaching style (Nigeria).



VIVA

Diabetic presenting with AKI and sepsis



Dr Imran Syed

DD 1/3

The image is a KUB X-ray. The spine is visible in the center. On the right side of the image (patient's left), there is a large, rounded, radiopaque mass, which is highly suggestive of a hydronephrotic kidney. The rest of the abdominal and pelvic structures are visible in a standard X-ray format.

=====XX=====XX=====